ACUTE OCULAR CHANGES THROUGH 60 GHZ MILLIMETER WAVE EXPOSURE

M. Kojima[1], Y. Yamashiro[2], M. Hanazawa[2], H. Sasaki[1], K. Wake[3], S. Watanabe[3], M. Taki[4], Y. Kamimura[5], K. Sasaki[2]

Department of Ophthalmology, Kanazawa Medical Uniersity[1], Division of Vision Research for Environmental Health, Kanazawa Medical University[2], National Institute of Information and Communications Technology[3], Department of Electrical Engineering Graduate School of Engineering, Tokyo Metropolitan University[4], Department of Information Science, Faculty of Engineering, Utsunomiya University[5]

1-1, Daigaku, Uchinada-machi, Kahoku-gun, Ishikawa-ken, 920-0293, JAPAN

m-kojima@kanazawa-med.ac.jp

INTRODUCTION

Millimeter wave bands have just started to be used in various wireless applications such as voice and data wireless transmission and collision avoidance devices for cars in our daily life. The effects of millimeter waves to the eye are only known in the superficial layers such as the corneal layers, the iris, and possibly the lens. This study was designed to investigate acute ocular changes, progression and healing in experimental rabbits.

MATERIALS AND METHODS

The eyes of pigmented rabbits (Dutch, 1.8-2.5 kg, 13-17 week-old) were exposed unilaterally to a 60 GHz millimeter wave with lens antenna（(-3 dB beam width: 6.02mm). The rabbits received 0.4% oxybuprocaine hydrochloride instillation for local anesthesia, and mixed-solutions of ketamine hydrochloride (5 mg/kg) + xylazine (0.23 mg/kg) were injected intramuscularly for systemic anesthesia prior to millimeter wave exposure and ocular examinations. The doses of 0.01, 1.5, and 3 W/cm^2 for 6 minute exposures were given to investigate the effects of acute ocular changes. The non-exposed contra lateral eyes of each rabbit were used as non-exposed controls. Ocular changes were evaluated by slit lamp, laser flare cell meter, specular microscope and iris angiography. For iris angiography, 10% sodium fluoresce was injected intravenously and observed by slit lamp with fluorescence excitation and blue light cut filter. Some crystalline lenses were enucleated and fixed with ethanol and acetate (4:1). Then lens flat preparations were performed to observe the condition of the lens epithelial cells. To adjust the millimeter wave exposure area, XY laser indicators and thermography were used.

ACKNOWLEDGEMENTS

The authors thank to Committee to promote research on the possible biological effects of electromagnetic fields.

RESULTS AND DISCUSSIONS

Fig. 1 indicates the conditions after 3 W/cm^2 exposures for 6 minutes. Miosis (black arrow, 8 out of 8 rabbits) and vasodilation (red arrow-head, 7 out of 8 rabbits) but no corneal opacity was observed immediately after exposure. Rosenthal et al. reported the corneal injury associated with high levels of epithelial damage immediately after 35 GHz exposure (25 mW/cm^2, 30 to 60 min. exposure duration) [1]. Rosenthal's results and ours differ in relation to physical damage of the corneal epithelium during exposure [2, 3]. Rosenthal placed a hone antenna in contact with the eye, and the animals' eyelids were taped open during exposure [1]. In our unpublished previous experiment, 30 minutes exposure duration for anesthetized rabbits induced corneal epithelial damage due to the effects of corneal drying. Corneal opacification (8 out of 8 rabbits) and corneal epithelial damage (fluorescein staining, 8 out of 8 rabbits) were seen one day after exposure. Corneal epithelial damage was seen from a day after (peak of epithelial cell damage) to a week after exposure (a slight change), and then it recovered. Corneal opacification became a peak 3 days after exposure and remained for over 7 weeks after exposure.

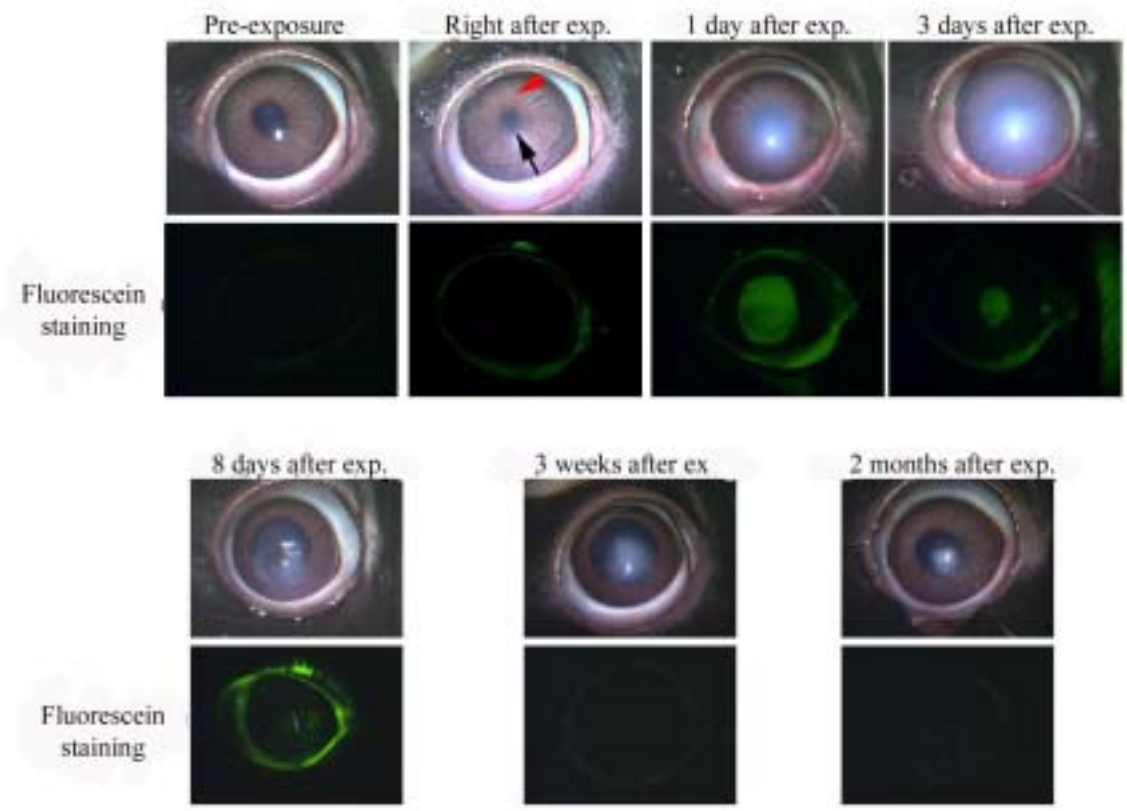

Fig. 1: Ocular changes after 3 W/cm^2 exposures

Lens flat preparations indicated abnormal lens epithelial cell formation 2 days after exposure. Higher epithelial cell density in the pupillary area (Fig.2 B&C, indicated by yellow arrow) was seen in the exposed eye, but not in the fellow eyes (Fig. 2 A). Under

higher magnification, abnormal lens epithelial cell nuclei accumulation was seen around the pupillary area (Fig. 2 C). Many mitotic cells (indicated by red arrow-head) were found outside the pupillary area and a few mitotic cells were inside the pupillary area. Epithelial cell damage or debris was not seen either inside or outside of the pupillary area. In general, lens epithelial cell in the pupillary area are not mitotic in normal conditions. The authors feel that some lens epithelial damage was induced during exposure. We need further experimentation before we can make any conclusions about lens epithelial damage by 60 GHz MMW exposure.

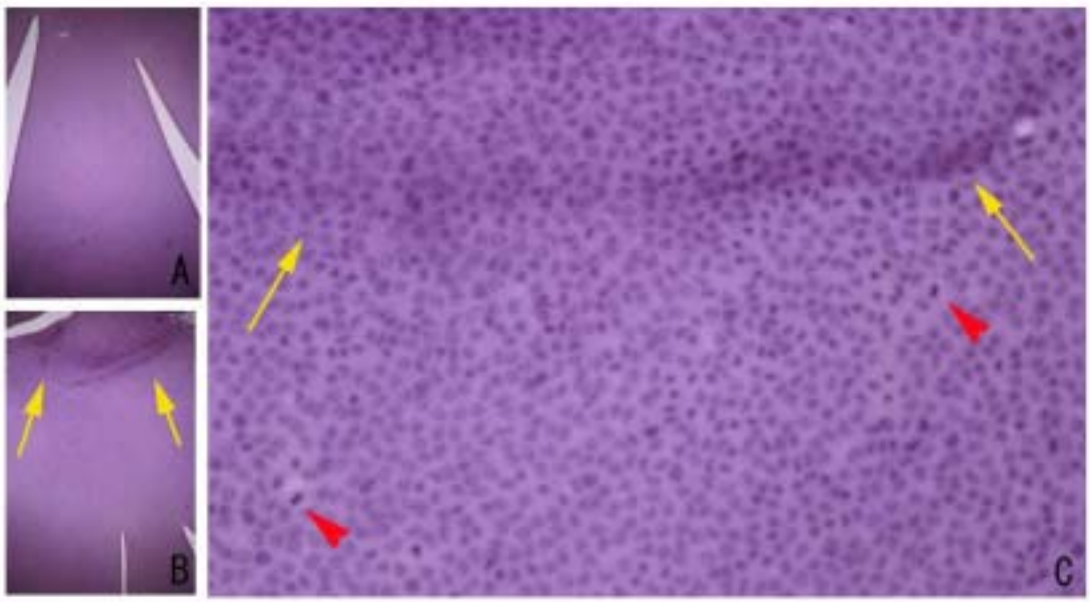

Fig. 2: Lens flat preparation. A: control eye. Original magnification on the film surface ×25 B: 2 days after exposure, ×25, C: 2 days after exposure, ×100

Through 6 minute 1.5 W/cm^2 exposures, slight corneal epithelial injuries (4 out of 4 rabbits), iris vasodilation (2 out of 4 rabbits), miosis (1 out of 4 rabbits), and ocular inflammations (2 out of 4 rabbits) were induced. All ocular changes were healed within a week in the 1,500 mW/cm^2 for 6 minutes exposure group.

0.01 W/cm^2 exposures did not show any ocular changes.

Fig. 3 showed the time course of flare value changes that indicated ocular inflammations. The 0.01 W/cm^2 exposure group showed no flare value change between before exposure and 1 day after exposure. Ocular inflammation of 1.5 W/cm^2 group peaked on 1day after exposure, then ocular inflammations gradually decreased, and disappeared within 3 days after exposure. The 3 W/cm^2 exposure group started to show strong ocular inflammation from immediately after exposure to 8 days after exposure. This inflammation was recovered gradually and disappeared within 3 weeks after exposure.

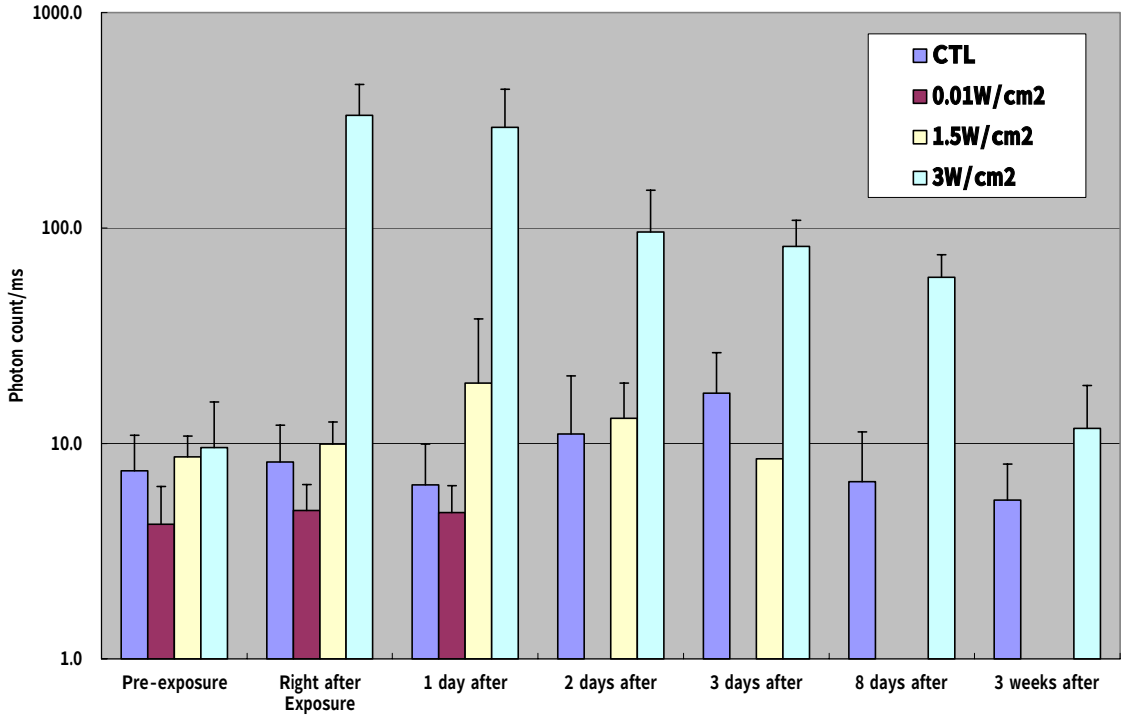

Time course of flare value n=4-8 rabbits' data in each point.

REFERENCES

1) S. W. Rosenthal, L. Birenbaum, I. T. Kaplan, W. Metlay, W.Z. Snyder, M. M. Zaret, "Effects of 35 and 107 GHz CW microwaves on the rabbit eye. Boulder, Colorado. HEW Publication (FDA) 77-8010, pp 110-128, 1977

2) H. Kues, S. A. D'Anna, R. Osiander, W. R. Green, J.C. Monahan, "Absence of ocular effects after either single or repeated exposure to 10 mW/cm^2 from a 60 GHz CW source. Bioelectromagnetics vol. 20, pp. 463-473, 1999

3) S. Chalfin, J.A. D'Andrea, P.D. Comeau, M. E. Belt, D. J. Hatcher, "Millimeter wave absorption in the nonhuman primate eye at 35 GHz and 94 GHz" Health Physics, vol. 83, pp. 83-90, 2002